



TABLE OF CONTENTS

Introduction

Treatment Options for Hemophilia

Isotopes

Safety Issues

Protocol for the Safe Use of
Radiosynovectomy: Key Points

Conclusion

References

Safe Use of Radiosynovectomy for Chronic Hemophilic Synovitis

James V. Luck, Jr, MD; Mauricio Silva, MD

December 22, 2010

Introduction

Radiosynovectomy, the ablation of synovial tissue by way of injected radiopharmaceuticals, has been in use for the treatment of hemophilic synovitis for more than 20 years in the United States.¹

Historically, radionuclides were used therapeutically for the relief of bone pain associated with metastatic cancer² and the management of rheumatoid arthritis.³ In recent years, however, it has become a life-altering procedure for patients with moderate to severe hemophilia who suffer from chronic, debilitating synovitis.

Such patients experience hemarthroses or joint bleeds, the recurrence of which can result in joint deterioration, deformity, and destruction of cartilage leading to partial or total ankylosis of the joint.⁴ Degenerative joint disease due to recurrent hemarthroses is a source of significant morbidity for hemophilia patients who, traditionally, have experienced life-long disability and interruption of physical and social activities.^{5,6}

According to estimates, approximately 25% of patients with hemophilia are candidates for radiosynovectomy—a large percentage given the number of cases of the disease on record worldwide. The World Federation of Hemophilia (WFH) puts this number at approximately 350,000 to 400,000, with 28,000 cases in the United States.^{4,7} The age-standardized ratio of patients with hemophilia is 1:10,000 in the pediatric population.⁴

Radiosynovectomy has become an increasingly utilized procedure within the hemophilia population.⁵ According to the National Hemophilia Foundation (NHF), there have been approximately 1100 procedures performed in 700 patients (children and adults) in the United States since 1988, when it was first practiced for this disease.⁸ Although early reports have been positive,^{9,10} with no direct association with malignancy, questions about its safety have been raised, especially in pediatric patients, based on 2 reports of acute lymphoblastic leukemia (ALL) in children with hemophilia following radiosynovectomy.^{1,8} Given the increasing use of radiosynovectomy for hemophilia and reports of malignancy in patients who have had the procedure, an examination of safety considerations is warranted.



For more information on radiosynovectomy, listen to Drs. Luck and Silva, pioneers in the use of the procedure, offer their clinical expertise on **“Radiosynovectomy in Hemophilia.”**

Treatment Options for Hemophilia

The treatment goal for patients with hemophilia is an aggressive containment of initial hemarthroses and elimination of recurrent joint bleeding in early childhood, before the development of chronic synovitis and

joint deterioration.^{5,11} Clotting factor replacement is the first-line treatment choice for hemophilic synovitis,¹² along with physical therapy and close follow-up.¹¹ Although primary and secondary prophylaxis regimens with regular infusions of clotting factor concentrate are considered the standard of care for the prevention and/or treatment of joint bleeds,^{1,13} this type of treatment can be difficult to maintain at times due to issues of cost, venous access, and compliance.^{1,13} Moreover, secondary prophylaxis has variable efficacy, and it is unclear whether it can prevent joint deterioration in patients with established chronic synovitis.⁵ Taking the above issues into account, radiosynovectomy appears to be a viable option. First used in the United States for rheumatoid arthritis, the procedure has been found to reduce the frequency of hemarthroses in the hemophilia patient population.¹²

The following patient types may benefit from use of radiosynovectomy^{2,5}:

- Patients in whom prophylactic factor replacement does not resolve chronic synovitis
- Poor surgical candidates as a result of factor VIII or factor FIX inhibitors
- Patients with advanced AIDS
- Patients without access to surgical options, such as arthroscopic synovectomy
- Patients who are noncompliant with rigorous physical therapy and factor infusion regimens

The procedure is also a cost-effective treatment option, averaging \$5000 USD compared to approximately \$112,000 USD for prophylaxis therapy with factor replacement (20-kg child; [Table 1](#)).¹³

Radiosynovectomy: Patient Contraindications

Not every person with hemophilia is a candidate for radiosynovectomy, which is a preventive measure only. Articular degeneration already present cannot be improved.¹¹ In a patient with advanced arthropathy who is experiencing chronic bleeds, radiosynovectomy can provide some pain relief. However, the patient needs to be informed that some of the pain might be related to arthritic changes and, as such, will not be improved with the synovectomy. Patients in this category tend to continue to deteriorate progressively, despite decreased joint bleeding.^{5,11} Additionally, patients with certain inherited conditions that increase sensitivity to radiation, such as Fanconi anemia or Bloom syndrome, should not be considered candidates for the procedure.⁵

Patient Case

RC, a 36-year-old male with severe hemophilia A (no inhibitors), presented to our center in 2001, complaining of frequent bleeding episodes on his left ankle. He reported having approximately 8 bleeds per month. Initial treatment consisted of regular clotting factor replacement for about 3 months, with no significant improvement in the frequency of bleeding.

Is this patient a good candidate for radiosynovectomy, based on the information provided?

- A) Yes
- B) No
- C) Not sure

Please log in to participate in this poll.

[View Results](#)

Case Outcome

The patient underwent a radiosynovectomy on the left ankle, using ³²P (chromic phosphate). During his first postprocedure visit, 1 month later, the patient indicated that his bleeding had completely disappeared. His left ankle has remained free of bleeding since that time, approximately 11 years.

Table 1. Financial Weight of Radiosynoviorthesis Relative to That for Alternative Therapies in a 20-kg Child

Treatment	20-kg child
Prophylaxis	\$111,630/year
Open Synovectomy	\$47,584
Arthroscopic Synovectomy	\$18,591
Radiosynoviorthesis	\$4732

Adapted from Manco-Johnson MJ, et al. *J Pediatr Hematol Oncol.* 2002;24:534-539.

Isotopes

“Not every available isotope has the same efficacy and safety.”¹²
Mauricio Silva, MD

A critical feature of radiosynovectomy is nuclide choice.³ The ideal isotope should be a pure beta emitter. The penetration depth of the emitted radiation (between 3 mm and 5 mm) should correspond to the thickness of the synovium in the joint to be treated.^{3,11} This isotope also should have a moderate half-life, to allow for a gradual rate of energy deposition, and be bound to carriers of sufficient molecular size (approximately 10 microns) to avoid the potential for leakage.^{3,4,11}

In the search for the ideal compound since colloidal gold (¹⁹⁸Au) was introduced in 1952, a large number of radionuclides in different chemical forms have been used for hemophilic arthropathy (**Table 2**), including Yttrium-90 (⁹⁰Y), rhenium-186 (¹⁸⁶Re), 32-P chromic phosphate (³²P), and dysprosium-165 (¹⁶⁵Dy).^{5,11}

While there has been European acceptance (EMA) of 3 nuclides for radiosynovectomy—⁹⁰Y for knee joints, ¹⁸⁶Re for mid-sized joints, and erbium-169 (¹⁶⁹Er) for finger and toe joints^{5,14}—the agent of choice in North America for hemophilic arthropathy is ³²P, although it does not have FDA approval for this indication.¹¹ It is currently FDA-approved only for interstitial or intracavitary use in the United States,^{5,15,16} with a well documented dosing and safety profile. In comparison, for chronic hemophilic synovitis, controversy exists regarding the optimal dose of radionuclide, and safety issues are not as well documented.

“In the low dose range up to a few tens of mSv, it is scientifically reasonable to assume that in general and for practical purposes cancer risk will rise in direct proportion to absorbed dose in organs and tissues.”¹⁷ International Commission on Radiological Protection (ICRP)

Table 2. Properties of Radiopharmaceuticals Used for Radiosynovectomy

Radiopharmaceutical	Particle size (nm)	Emission (β: beta; γ: gamma)	Energy (MeV)	Half-life (days)	Penetration mean/max (mm)	Main use/adult dose (MBq)
Y-90 silicate or citrate colloid	100	β	2.2	2.7	3.6/11	Knee joint; 185
Re-186 sulfide colloid	5-10	β, γ	1.0	3.72	1.2/3.6	Hip, shoulder; 74-185 Elbow, wrist, ankle; 74
Er-169 citrate colloid	10	β	0.34	9.4	0.3/1	Small joints of hands and feet; 37
P-32 colloid	500-2000	β	1.7	14	2.6/7.9	Knee, elbows and ankles; 10-40

Posted with permission from Turkmen C. *J Coagul Disord.* 2009;1-8.

Safety Issues

For any radionuclide, it is difficult to determine the exact amount of activity to achieve a therapeutic

response. For optimal effect, it is believed that approximately 100 Gy/100 g of synovial tissue should be absorbed.⁸ With radiosynovectomy, there is a theoretical concern that circulating lymphocytes may experience increased retention time in inflamed synovium.¹² In North America, the procedure has not had a long history in hemophilia patients, approximately 30 years; nevertheless, no malignancies have ever been reported with its use.¹⁴ Only recently, there were reports of leukemia in 2 hemophilic children after treatment with the ³²P isotope.¹³ As a result, ³²P has come under scrutiny.

The first reported case of leukemia (ALL) occurred in a 9-year-old boy with severe hemophilia A. He had received ³²P injections into the left elbow and right ankle 3 months prior to the diagnosis of hyperdiploid B precursor ALL.¹ The second case involved a 14-year-old male with severe hemophilia A who had received ³²P injections into the left elbow and right ankle. Ten months later, he was found to have an anterior mediastinal mass and leukocytosis.¹ There was no detectable radiation leakage reported in either case.

Although ALL is the most common childhood malignancy, with a yearly incidence of 1/2500 children younger than 15 years,^{8,13} based on estimates from the CDC, NCI, and SEER, there should have been only 1.5 cases in the hemophilia population over the past 10 years.⁸ According to the latest recommendations of the Medical and Scientific Council (MASAC) of the NHF, "The causal relationship between radiation exposure and malignancy [in the reported cases] cannot be established conclusively, but possible causality cannot be ruled out."⁸ The two reported cases prompted Covidien, the manufacturer of ³²P at the time (Phosphocol® P32) to issue a warning letter to physicians, cautioning them about off-label use of the radionuclide,¹⁵ which has been used frequently for hemophilic synovitis. According to a survey of hemophilia treatment centers in the United States, between 1017 and 1027 ³²P injections were administered to nearly 580 patients who have had radiosynovectomies since 1988.¹

The efficacy of ³²P for radiosynovectomy has been documented in several studies conducted within the past decade. One of the largest studies examined 130 joints with an average follow-up of 36.5 months. It was found that 79.2% of primary procedures achieved excellent and good results, with a reduction in hemarthroses from 75% to 100%. Moreover, radiation was well contained within the joint.¹²

In a separate study of 125 joints treated with ³²P, there was a 50% or greater decline in frequency of joint bleeds 2 to 10 years postprocedure, and no evidence of significant leakage was observed.¹⁰

A more recent study, conducted by Infante-Rivard and colleagues (2006), directly addressed issues of safety with ³²P. This retrospective, long-term Canadian study evaluated the incidence of cancer in more than 2400 patients with chronic synovitis.^{19,20} The incidence rates of cancer in patients treated with radiosynovectomy were compared to the incidence rates of cancer in the general population of Québec. Study investigators found no evidence of an increased cancer risk with the use of radiosynovectomy.^{19,20}

No definitive conclusions can be drawn about the safety of radiosynovectomy. However, there are ways to minimize potential dangers associated with the procedure. For example, it is recommended that repeat dosing of radionuclides be spaced at 3-month intervals or greater.² It is also recommended that the treated joint be immobilized for 48 hours postprocedure to potentially avoid leakage of the radionuclide material and minimize inflammation at the injection site (see [Figure 1](#)).²

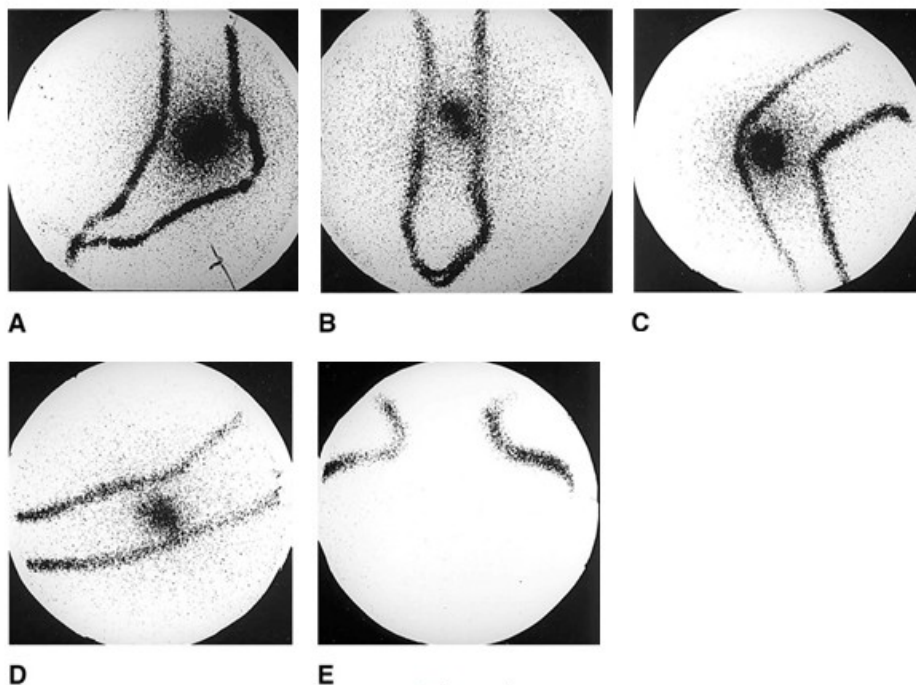


Figure 1

Lateral (A) and anteroposterior (B) views of right foot and ankle 24 hours after radiosynovectomy for chronic hemarthropathy and synovitis of the right ankle. The scan demonstrates confinement of the P-32 chromic phosphate radioisotope to the ankle joint as well as homogeneous distribution of activity. Outlines result from radioimaging marking pens. Lateral (C) and anteroposterior (D) views of right elbow, and anteroposterior (E) view of ipsilateral axilla 24 hours after radiosynovectomy for chronic hemarthropathy and synovitis of the right elbow. The scan demonstrates homogeneous distribution of the P-32 chromic phosphate radioisotope with the absence of activity in the ipsilateral axillary nodes.

© 2004 American Academy of Orthopaedic Surgeons. Reprinted from the *Journal of the American Academy of Orthopaedic Surgeons*, Volume 12(1), pp. 55-64 with permission.

Protocol for the Safe Use of Radiosynovectomy: Key Points

Clinicians should consider the following before undertaking radiosynovectomy in their patients⁵:

Pre-Procedure

1. Begin factor prophylaxis at least 2 to 4 weeks prior to procedure (longer if clinically indicated)
2. Obtain an inhibitor screen (within 3 months of procedure)
3. Obtain informed consent
4. Before procedure (may be individualized)
 - Noninhibitor patients: 80%-100% correction dose and obtain a factor level 15 min postinfusion
 - Inhibitor patients: 75-100 U/kg of activated prothrombin complex concentrate or 90-120 µg/kg of recombinant factor VIIa
5. Apply topical anesthetic cream to injection site 1 h prior to procedure
6. Baseline Geiger counter scan of both joints, regional nodes, sternum, and liver
7. Review current imaging studies of joint (within last 3 months) and record Pettersson score
8. Record pre-procedure range of motion, synovial exam, and articular exam of affected joint

Procedure

1. Antiseptic preparation of injection site
2. Infiltrate injection site with buffered 1% lidocaine without epinephrine using a small gauge needle
3. Insert 22-gauge needle into joint and attempt to aspirate
4. Obtain arthrogram with nonionic contrast and fluoroscopic guidance if localization is in doubt
5. P-32 chromic phosphate dosimetry
 - Patients >30 kg: 1 mCi for large joints, 0.5 mCi for small joints
 - Patients <30 kg: 0.5 mCi for large joints, 0.25 mCi for small joints
6. Inject 2-3 mCi of 99mTc sulfur colloid/albumin colloid concomitant with P-32 injection
7. Flush with triamcinolone hexacetonide 20-40 mg and 5-10 cm³ of 0.5% bupivacaine HCl with epinephrine during withdrawal of needle
8. Bandage and apply pressure for 5 min
9. SPECT image joint for loculation of radionuclide

Post-Procedure

1. Apply continuous air cast and immobilize 48-72 h
2. Pain control as needed

3. Consider post-procedure factor replacement
4. Follow-up Geiger scans at 1 day, 1 week, and 1 month post-procedure, with 10 s counts over treated and contralateral joint, ipsilateral and contralateral draining lymph nodes, sternum, and liver
5. Clinical examination day 1 post-injection and months 3, 6, 9, and 12
6. Resume prophylaxis or episodic treatment as clinically indicated or as per institutional guidelines
7. Reinitiate physical therapy 7 days post-procedure if clinically indicated

Posted with permission from Dunn AL, et al. *Thromb Haemost.* 2002;87:383-393.

Additionally, MASAC has recommended [guidelines](#) for clinicians to consider before performing radiosynovectomy in their patients with chronic synovitis.⁸

Conclusion

Although radiosynovectomy appears to be a safe procedure, the possibility of developing a malignancy remains a question that further studies need to address. Clinicians should counsel patients about inherent safety risks. Additionally, close interdisciplinary collaboration with the hematologist, orthopedist, and nuclear medicine specialist is called for, as is the need for a national registry that addresses safety issues pertaining to radiosynovectomy. With steps in place to ensure the safety of hemophilia patients who experience the complication of chronic synovitis, radiosynovectomy represents a potentially life-changing treatment option.

REFERENCES

1. Dunn AL, Manco-Johnson M, Busch MT, Balark KL, Abshire TC. Leukemia and P32 radionuclide synovectomy for hemophilic arthropathy. *J Thromb Haemost.* 2005;3:1541-1542.
2. Siegel HJ, Luck JV Jr, Siegel ME. Advances in radionuclide therapeutics in orthopaedics. *J Am Acad Orthop Surg.* 2004;12:55-64.
3. Kampen WU, Voth M, Pinkert J, Krause A. Therapeutic status of radiosynoviorthesis of the knee with yttrium [⁹⁰Y] colloid in rheumatoid arthritis and related indications. *Rheumatology (Oxford).* 2007;46:16-24.
4. Barrenechea E. Radiosynovectomy. PowerPoint presentation. Available at: http://www.sgh-nmu.org/documents/day3-7th_march/Barrenechea.pdf. Accessed June 14, 2010.
5. Dunn AL, Busch MT, Wyly JB, Abshire TC. Radionuclide synovectomy for hemophilic arthropathy: a comprehensive review of safety and efficacy and recommendation for a standardized treatment protocol. *Thromb Haemost.* 2002;87:383-393.
6. Turkmen C. Safety of radiosynovectomy in hemophilic synovitis: it is time to re-evaluate. *J Coagul Disord.* 2009;1-8.
7. World Federation of Hemophilia. Guidelines for the Management of Hemophilia. Available at: http://www.wfh.org/2/docs/Publications/Diagnosis_and_Treatment/Gudelines_Mng_Hemophilia.pdf. Accessed October 29, 2010.
8. National Hemophilia Foundation. MASAC Recommendations Regarding Radionuclide Synovectomy. Document # 194. Available at: <http://www.hemophilia.org/NHFWeb/MainPgs/MainNHF.aspx?menuid=57&contentid=692>. Accessed October 26, 2010.
9. Rivard G-E, Girard M, Bélanger R, Jutras M, Guay J-P, Marton D. Synoviorthesis with colloidal ³²P chromic phosphate for the treatment of hemophilic arthropathy. *J Bone Joint Surg Am.* 1994;76:482-488.
10. Siegel HJ, Luck JV Jr, Siegel ME, Quinones C. Phosphate-32 colloid radiosynovectomy in hemophilia: outcome of 125 procedures. *Clin Orthop Relat Res.* 2001;(392):409-417.
11. Silva M, Luck JV Jr, Llinás A. *Chronic Hemophilic Synovitis: The Role of Radiosynovectomy.* World Federation of Hemophilia. April 2004. Available at: http://www.wfh.org/2/docs/Publications/Musculoskeletal_Physiotherapy/TOH-33_English_Synovectomy.pdf. Accessed October 29, 2010.
12. Silva M, Luck JV Jr, Siegel ME. ³²P chromic phosphate radiosynovectomy for chronic haemophilic synovitis. *Haemophilia.* 2001;7(suppl 2):40-49.

13. Manco-Johnson MJ, Nuss R, Lear J, et al. ^{32}P radiosynoviorthesis in children with hemophilia. *J Pediatr Hematol Oncol*. 2002;24:534-539.
14. Kavakli K, Cogulu O, Aydogdu S, et al. Long-term evaluation of chromosomal breakages after radioisotope synovectomy for treatment of target joints in patients with haemophilia. *Haemophilia*. 2010;16:474-478.
15. Chromic Phosphate P32 Suspension [prescribing information]. Tampa, FL: AnazaHealth Corporation.
16. Phosphocol[®] P32 [prescribing information]. St. Louis, MO: Mallinckrodt, Inc; 1992.
17. International Commission on Radiological Protection. 2005 Recommendations. Available at: http://www.icrp.org/consultation_view.asp?recommendation={7F99AD32-903D-4B7B-93AB-49549A62CEE6}. Accessed October 28, 2010.
18. National Hemophilia Foundation. Company issues warnings after patients develop leukemia. Available at: <http://www.hemophilia.org/NHFWeb/MainPgs/MainNHF.aspx?menuid=118&contentid=1160>. Accessed June 14, 2010.
19. Infante-Rivard C, Rivard G, Winikoff R, Derome F, Chartrand R, Guay J. Is there an increased risk of cancer associated with radiosynoviorthesis? *Haemophilia*. 2006;12(suppl 2):80-90.
20. Rodriguez NI, Hoots WK. Advances in hemophilia: experimental aspects and therapy. *Hematol Oncol Clin North Am*. 2010;24:181-198.

This initiative is supported by an educational grant from:



This initiative is jointly sponsored by:

